

# Monoclonal Antibody Analysis of Keratin Expression in Epidermal Diseases: A 48- and 56-kdalton Keratin as Molecular Markers for Hyperproliferative Keratinocytes

ROBERT A. WEISS,\* RIVA EICHNER,\*<sup>§</sup> and TUNG-TIEN SUN\*\*<sup>§</sup>†

Departments of \*Dermatology, <sup>†</sup>Ophthalmology, and <sup>§</sup>Cell Biology and Anatomy, The Johns Hopkins University School of Medicine, Baltimore, Maryland 21205; and Departments of <sup>†</sup>Dermatology and Pharmacology, New York University School of Medicine, New York 10016.

**ABSTRACT** The polypeptide composition of epidermal keratin varies in disease. To better understand the biological meaning of these variations, we have analyzed keratins from a number of human epidermal diseases by the immunoblot technique using AE1 and AE3 monoclonal antikeratin antibodies. The results reveal a continuous spectrum of keratin expression ranging from one closely resembling the normal in vivo pattern to one almost identical to cultured epidermal keratinocytes. Specifically, a 50-kilodalton (kd) (AE1-positive) and a 58-kd (AE3-positive) keratin are present in all diseases, supporting the concept that they represent "permanent" markers for keratinocytes. A 56.5-kd (AE1) and a 65–67-kd (AE3) keratin, previously shown to be markers for keratinization, are expressed only by lesions retaining a keratinized morphology. A 48-kd (AE1) and a 56-kd (AE3) keratin are present in all hyperproliferative (para- or nonkeratinized) disorders, but not in normal abdominal epidermis or in ichthyosis vulgaris which is a nonhyperproliferative disease. These two keratins have previously been found in various nonepidermal keratinocytes undergoing hyperproliferation, suggesting that these keratins are not epidermis-specific and may represent markers for hyperproliferative keratinocytes in general. In various epidermal diseases, there is a reciprocal expression of the (keratin) markers for hyperproliferation and keratinization, supporting the mutual exclusiveness of the two cellular events. Moreover, our results indicate that, as far as keratin expression is concerned, cultured human epidermal cells resemble and thus may be regarded as a model for epidermal hyperplasia. Finally, the apparent lack of any major, disease-specific keratin changes in the epidermal disorders studied so far implies that keratin abnormalities probably represent the consequence, rather than the cause, of these diseases.

The keratins are a group of water-insoluble proteins (40–70 Kdaltons [kd])<sup>1</sup> that form 10-nm desmosome-associated tonofilaments in all epithelia (15, 17, 18, 61, 63, 64). Four major keratins (50, 56.5, 58, and 65–67 kd) have been identified in normal human epidermis (7, 21, 40, 72; cf. 4, 49, 62); significant alterations in epidermal keratin composition can occur, however, as a result of disease (1, 3, 5, 25, 26, 28, 33, 34, 36, 37, 40, 50, 52, 54, 66, 71) as well as changes in cellular growth environment (10, 20, 29, 55, 61, 62).

Numerous attempts have been made to characterize such

keratin variations in epidermal diseases. Recent studies have demonstrated that some, but not all, psoriatic epidermal specimens possess a reduced level of 65–67-kd keratins (1, 5, 8, 37, 50, 54, 66). In addition, Thaler et al. (65, 66) reported that two water-insoluble proteins of ~54 and 57 kd are unique to psoriatic scale, although Baden et al. (5) found no "psoriasis-specific" keratin changes. Hunter and Skerrow (26) reported that certain abnormal keratin polypeptides ranging from 55–63 kd (probably corresponding to 50–58 kd in our gel system) are present in the scales of psoriasis, atopic dermatitis, and seborrheic dermatitis, as well as in the stratum corneum of tape-stripped epidermis. Interestingly, Kubilus et al. (28) found that keratins of another disease, basal cell

<sup>1</sup> Abbreviations used in this paper: BCC, basal cell carcinoma; IEF, isoelectric focusing; kd, kilodaltons.

carcinoma (BCC), are similar to those synthesized by cultured normal human keratinocytes. Moll et al. (40) further demonstrated that BCC expresses a 46-kd keratin that is present in cells of the pilosebaceous unit but absent in interfollicular epidermis. Finally, Steinert et al. (54) analyzed keratins isolated from several epidermal disorders including psoriasis, lamellar ichthyosis, and Darier's disease. They found variable amounts of small molecular weight components (<50 kd) in all specimens, presumably due to an elevated level of protease activity in diseases. These results firmly established that keratin expression can be affected by various disease states. However, since results from different laboratories have not always been consistent with one another, the significance of such findings is unclear, and the existence of disease-specific keratins remains controversial.

We have previously described the preparation and characterization of several mouse monoclonal antikeratin antibodies (72). Two of these antibodies, designated AE1 and AE3, recognize two mutually exclusive subfamilies of keratins. Keratins of the AE1 (or A) subfamily are relatively acidic, whereas those of the AE3 (or B) subfamily are relatively basic (12). In combination, the two antibodies recognize most known keratin species (12, 57, 58, 68, 72) and therefore provide an excellent tool for studying epithelial keratin expression.

In the presence of lethally irradiated 3T3 feeder cells, human epidermal keratinocytes form stratified colonies and undergo terminal differentiation (47). However, unlike the normal epidermis which is keratinized, cultured cells fail to form the granular layer and enucleated cornified layers and therefore may be described as "nonkeratinized" (31, 47). Using monoclonal antikeratin antibodies, we have recently demonstrated that a 50-kd keratin (recognized by AE1 antibody) and a 58-kd keratin (AE3) are expressed by epidermal cells, both in vivo and in culture (12; also see 21). In addition to these two keratins, in vivo epidermis expresses a 56.5-kd (AE1) and a 65–67-kd keratin (AE3), which are made only during advanced stages of epidermal differentiation (59, 72; cf. 21, 51) and thus may be regarded as molecular markers for keratinization (59, 68, 72). Instead of synthesizing these "keratinization markers," cultured epidermal cells are characterized by a 48- (AE1), a 56-kd (AE3), and several other keratins not detectable in normal epidermis (12, 21, 62). The significance of these "culture-type" keratins remains unclear.

We demonstrate in this paper that the 48- and 56-kd "culture-type" keratins are present not only in various cultured keratinocytes (12, 62, 73), but also in all hyperproliferative epidermal diseases examined so far. Such results suggest that these two keratins may be regarded as markers for hyperproliferative keratinocytes.

## MATERIALS AND METHODS

**Monoclonal Antibodies:** The preparation and characterization of AE1, AE2, and AE3 monoclonal antikeratin antibodies have been described in detail previously (68, 72).

**Patient Selection:** Specimens of epidermal diseases were obtained by 4-mm punch biopsy, excisional biopsy, shave biopsy, or curettage in the outpatient dermatology clinic at the Johns Hopkins Hospital. The total number of epidermal disease samples studied were as follows: psoriasis (10 cases), ichthyosis vulgaris (1), contact dermatitis (2), atopic dermatitis (2), dermatomyositis (2), keratoacanthoma (2), actinic keratosis (2), verruca vulgaris (wart) (2), verrucous carcinoma (1), Bowen's disease (1), squamous cell carcinoma (3), and basal cell carcinoma (4). A portion of the samples was fixed in formaldehyde for routine histology (hematoxylin and eosin staining); the re-

maining tissue was flash-frozen in liquid nitrogen and stored at  $-70^{\circ}\text{C}$  prior to protein extraction. Keratins isolated from normal human abdominal, breast, and back skin as well as neonatal foreskin (exterior, nonmucosal portion) were used as controls, with similar results.

**Keratin Extraction:** Instead of using cornified cells (also called scales or stratum corneum) whose keratins are partially degraded (7, 21, 53, 72), we isolated keratins from intact epidermis predominantly represented by living layers. The epidermal portions of various diseases, normal skin, or cultured human keratinocytes were minced and homogenized at  $4^{\circ}\text{C}$  in ~50–100 volume (vol/wt) of 25 mM Tris HCl (pH 7.4) containing the following protease inhibitors: 1 mM phenylmethylsulfonyl fluoride (PMSF), antipain (10  $\mu\text{g}/\text{ml}$ , Sigma Chemical Co., St. Louis, MO), pepstatin (5  $\mu\text{g}/\text{ml}$ , Sigma Chemical Co.), 1 mM EDTA, and 1 mM EGTA. After centrifugation (10,000 for 10 min at  $4^{\circ}\text{C}$ ), the keratin-containing pellet was recovered and heated at  $95^{\circ}\text{C}$  for 5 min in a solution containing 25 mM Tris HCl (pH 7.4), 5% 2-mercaptoethanol, and 1–5% SDS. For two-dimensional gel electrophoresis, a portion of the water-insoluble pellet was extracted at room temperature for 15 min with a buffer containing 9.5 M urea, 50 mM dithiothreitol, and 25 mM Tris HCl buffer (pH 7.4) (72).

**Gel Electrophoresis and Immunoblot Analysis:** One-dimensional (Laemmli-type) SDS-polyacrylamide gel electrophoresis (SDS PAGE; 12.5% acrylamide) was performed as previously described (62). Equilibrium and nonequilibrium two-dimensional gel electrophoresis were done according to O'Farrell et al. (44, 45). One- and two-dimensional immunoblot analyses using the peroxidase-antiperoxidase technique were done as described earlier (12, 67, 72).

**Cell Culture:** Secondary cultures of newborn human foreskin-derived epidermal cells were grown in the presence of lethally irradiated (4,000 Rads) 3T3 feeder cells (47). Keratins were extracted from both sparse (exponentially growing) and confluent cultures, with similar results.

## RESULTS

### *A 48- and a 56-kd Keratin Were Present in a Wide Variety of Epidermal Diseases*

To determine the possible correlation between the expression of specific keratins and certain abnormal features of epidermal differentiation, we have analyzed keratins isolated from various human epidermal diseases. Ichthyosis vulgaris, which is characterized by a decreased granular layer, was used as an example of a nonhyperproliferative epidermal disorder. Benign hyperproliferative diseases studied include psoriasis (a common disease of unknown etiology), verruca vulgaris (human papilloma virus-induced hyperproliferation; also known as common wart), actinic keratosis (solar damage-induced hyperproliferation), and keratoacanthoma (a rapidly growing, benign tumor which resembles squamous cell carcinoma). The malignant hyperproliferative diseases studied include basal cell carcinoma, squamous cell carcinoma, and verrucous carcinoma (a verruca-like squamous cell carcinoma). Other epidermal disorders studied include a variety of dermatitis in which the epidermis is believed to be in a hyperproliferative state when regenerating; these included atopic dermatitis, contact dermatitis, and dermatomyositis. Keratins of these epidermal disorders were compared with those isolated from normal epidermis and cultured newborn foreskin epidermal cells.

Water-insoluble cytoskeletal proteins were extracted from various epidermal specimens in the presence of a mixture of protease inhibitors (see Materials and Methods) and analyzed by SDS PAGE. Protein staining revealed several interesting points (Fig. 1*a*). First, the 50- and 58-kd keratins, which are expressed by both normal epidermis and cultured keratinocytes (12, 21), were present in all epidermal diseases. Second, the 65–67 kd keratin, a marker for phenotypic keratinization (58, 59, 68, 72; cf. 10, 22, 39), was diminished in many diseases, perhaps reflecting a decreased degree of morphological keratinization. A complete loss of this keratin was rou-

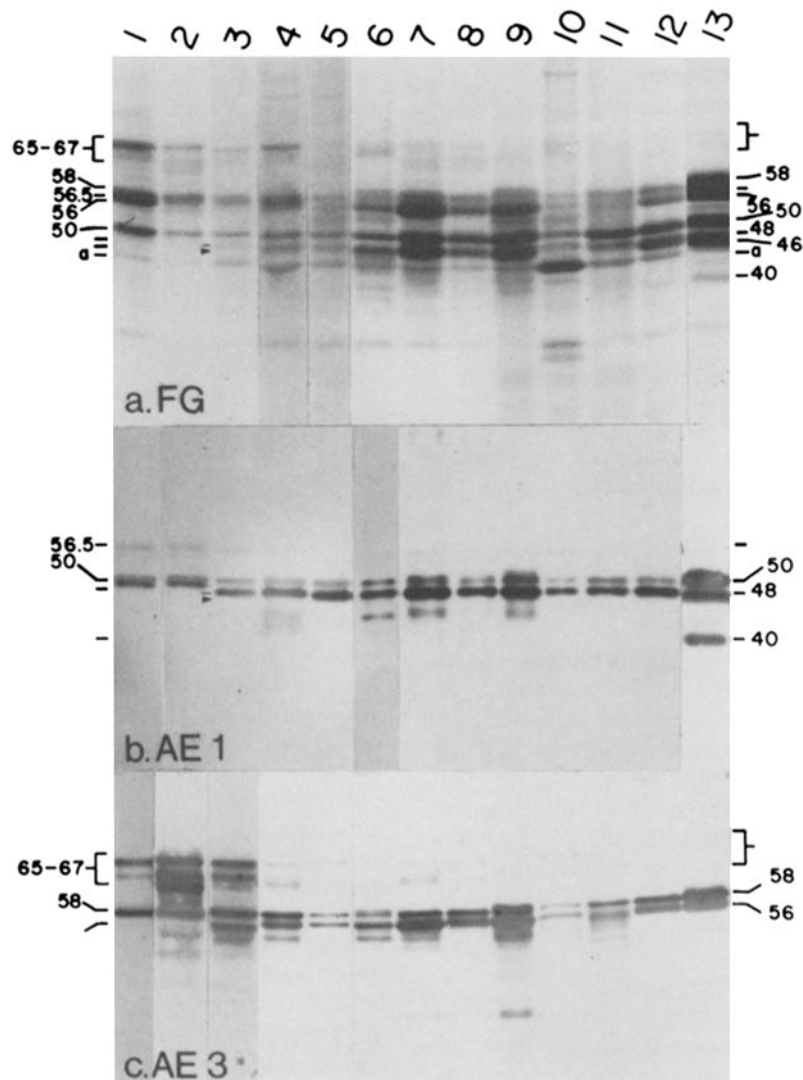


FIGURE 1 Immunoblot analysis of keratins isolated from various epidermal diseases. (a) Fast green (FG) staining: lane 1, keratins of normal abdominal skin; lane 2, ichthyosis vulgaris; lane 3, atopic dermatitis (bar and arrowhead designate the 48- and 46-kd keratins, respectively, which are only partially resolved by 1-D gels); lanes 4 and 5, two different cases of psoriasis showing different amounts of 65–67 kd keratins; lane 6, keratoacanthoma; lane 7, actinic keratosis; lane 8, wart; lane 9, verrucous carcinoma; lanes 10 and 11, two different cases of squamous cell carcinoma showing slightly different keratin patterns; lane 12, basal cell carcinoma; lane 13, cultured normal human epidermal keratinocytes. Note the striking similarity between the overall keratin pattern of some diseases and that of cultured epidermal cells. The sharpness of keratin bands suggests that the great majority of the keratins must have originated from epidermal living layers (72) (b) Immunoblot staining of the same samples using AE1 monoclonal antibody which selectively reacts with keratins of subfamily A (see reference 12). Note the detection of a 48-kd keratin (bar) in all hyperproliferative diseases. Also note the decreased amounts of 56.5-kd keratin in many hyperproliferative diseases, the ubiquitous presence of 50-kd keratin in all specimens, and the absence of 40-kd keratin in diseases. The small molecular weight (<48 kd) AE1-reactive components in lanes 4, 6, 7, and 9 may represent degradative products. (c) Immunoblot staining of the same samples using AE3 monoclonal antibody which selectively recognizes keratins of subfamily B (12). Note the detection of a 56-kd keratin in all hyperproliferative diseases. Also note the presence of a 58-kd keratin in all samples, and the decreases in the 65–67-kd keratins in many diseases (cf. gel b). The small molecular weight, AE3-reactive species (<56 kd) in lanes 4, 6, 7, and 9 are presumably proteolytic degradative products (cf. Fig. 1 b). Values represent keratin molecular weight  $\times 10^{-3}$ .

tinely observed in “undifferentiated” basal cell carcinomas (Fig. 1, lane 12; [28, 39, 40]), consistent with their nonkeratinized morphology. Third, a 46/48-kd doublet and a 56-kd band, similar to those of cultured keratinocytes, were detected in most diseases except in nonhyperproliferative ichthyosis vulgaris. Finally, there appeared to be a spectrum of keratin expression ranging from an almost normal *in vivo* pattern (ichthyosis vulgaris) to that of cultured epidermal keratinocytes (e.g., basal cell carcinomas, squamous cell carcinomas,

and some specimens of benign diseases; Fig. 1 a, lanes 7–12; also see below). The keratin patterns of many specimens were intermediate between these two extremes and represented a combination, with various proportions, of the *in vivo* and *in vitro* keratin components.

To further characterize these keratins, we analyzed them by the immunoblot technique using AE1 and AE3 monoclonal antikeratin antibodies (72). Consistent with our earlier results (12, 72), AE1 recognized in normal epidermis a 56.5-

kd keratin (a keratinization marker) and a 50-kd keratin (a marker for stratified epithelia; Fig. 1*b*, lane 1); and in cultured cells a 50-, a 48-, and a 40-kd keratin (Fig. 1*b*, lane 13). Immunoblot analysis of abnormal epidermal tissues (Fig. 1*b*) showed that the 50-kd keratin was ubiquitous and that the 56.5-kd keratin was diminished in many diseases. Also, as shown earlier (12), AE1 reacted strongly with the 48-kd but not the 46-kd component of the 46/48-kd doublet of cultured keratinocytes. This AE1-reactive 48-kd keratin was clearly demonstrated in all diseases that are hyperproliferative, but not in normal abdominal epidermis or nonhyperproliferative ichthyosis vulgaris (Fig. 1*b*). A few low molecular weight AE1-reactive species were occasionally detected which probably represented proteolytic fragments of keratins (54), despite the inclusion of several protease inhibitors in our extraction buffers. Finally, no well-defined 40-kd keratin was detected in any of the epidermal diseases, neoplasms included (Fig. 1*b*).

The results obtained by AE3 staining (Fig. 1*c*) were strikingly parallel to those of AE1 staining. In normal human epidermis, AE3 recognized the 65–67-kd keratin (a keratinization marker) that, like the AE1-reactive 56.5-kd keratin, was present in diminished amounts in many diseases. The 58-kd keratin (a marker for stratified epithelia), like the AE1-reactive 50-kd keratin, was common to normal epidermis, cultured cells, and all diseases. In addition, AE3 antibody staining demonstrated that the 56-kd keratin, like the AE1-reactive 48-kd keratin, was present in almost all hyperproliferative diseases as well as cultured keratinocytes, but not in normal abdominal epidermis or ichthyosis vulgaris (Fig. 1*c*).

### Expression of Both "In Vivo" and "Culture" Types of Epidermal Keratins in Diseases

To better characterize the keratins of various diseases, we analyzed them by two-dimensional polyacrylamide gel electrophoresis in which the proteins were first resolved by isoelectric focusing (IEF) or nonequilibrium pH gradient (NEpHG) electrophoresis followed by SDS gel electrophoresis. After being transferred to nitrocellulose paper, the proteins were visualized by Fast green staining. Fig. 2, *a–c* show the IEF-SDS gel patterns of the keratins of normal epidermis (Fig. 2*a*), cultured keratinocytes (Fig. 2*b*), and psoriasis (Fig. 2*c*); Fig. 2, *a'–c'* show the immunoblot results of the corresponding gels with AE1 antibody. As shown earlier, keratins of the AE1 (or A) subfamily are relatively acidic (12) and are well resolved in this gel system (62, 72). The results indicated the following: first, a 50-kd keratin and a more acidic "50'-kd" variant were present in all specimens; second, the 56.5-kd keratin (and its 55–56 kd, AE1-positive, degradative product, [72]) was present in normal epidermis and psoriasis, but not in cultured keratinocytes; and, third, the 48-kd keratin was present in psoriasis and cultured keratinocytes, but not in normal abdominal epidermis. These results indicated that, within the AE1 keratin subfamily, psoriatic epidermis could express both *in vivo* and culture keratin types (except for the 40-kd keratin, see below).

Two-dimensional gel electrophoresis in which the first dimensional separation was done under nonequilibrium conditions allowed the simultaneous resolution of both acidic and basic epidermal keratins (instead of only the more acidic AE1-reactive keratins by IEF; [16, 40, 74]). The results were entirely consistent with those obtained by one-dimensional

SDS gels and two-dimensional IEF-SDS gels and provided further evidence that an acidic, AE1-reactive 48-kd keratin (Fig. 3 and data not shown) and a basic, AE3-reactive 56-kd keratin (Fig. 3 and data not shown), that were absent in normal abdominal epidermis (Fig. 3*a*) and ichthyosis vulgaris (Fig. 3*c*), were common to cultured keratinocytes (Fig. 3*b*) and a wide variety of hyperproliferative diseases including psoriasis (Fig. 3*d*), wart (Fig. 3*e*), and basal cell carcinoma (Fig. 3*f*).

### A Spectrum of Keratin Expression in a Single Disease (Psoriasis): Morphological Correlations

In the experiments described above, each disease was treated as a separate entity. Previous results have indicated, however, that variations in keratin expression may exist even within a given disorder (3–5, 8, 34, 50, 54, 66). To determine the possible relationship between the expression of the 48- and 56-kd keratins and specific morphological features within a disease, we studied keratin expression in 10 cases of psoriasis. Analysis of their keratins by SDS PAGE (Fig. 4*a*) and immunoblot technique (Fig. 1 and data not shown) revealed a spectrum of keratin expression. The keratin patterns varied from one closely resembling the normal *in vivo* pattern (Fig. 4*a*, lanes 2 and 3) to one almost indistinguishable from cultured keratinocytes (Fig. 4*a*, lane 4). Histological examination (Fig. 4*b*) showed that the disappearance of the 56.5 and 65–67-kd keratins and the appearance of the "culture type" keratins correlated well with the degree of parakeratinization (as defined by the lack of a granular layer and the formation of an abnormal, nucleated stratum corneum [32]). These findings confirmed and extended earlier results by Baden (5), Skerrow (25, 50), Thaler (66), and Bowden (8) and their co-workers, and provided additional evidence that the 56.5- and the 65–67-kd keratins may serve as molecular markers for morphological keratinization (68, 72). Our data also suggested a strong correlation between the expression of 56- and 48-kd keratins and the degree of abnormal epidermal growth and/or differentiation.

This continuous spectrum of keratin expression as observed in psoriasis (Fig. 4) and other epidermal diseases (Fig. 1) is schematically summarized in Fig. 5.

## DISCUSSION

### A 48- and a 56-kd Keratin as Molecular Markers for Hyperproliferative Keratinocytes

In the present study, we have identified a 48- and a 56-kd keratin in many epidermal disorders. Although elevated protease activities have been suggested for certain diseases (14, 54), it seems highly unlikely that these two polypeptides represent degradative products of some higher molecular weight keratin components, for the following reasons. First, cultured epidermal cells expressed keratins that were identical to the 48- and 56-kd components of the diseases according to one- and two-dimensional gel electrophoretic mobilities, as well as reactivities with monoclonal antikeratin antibodies (Figs. 1–3). Cell-free translation experiments showed that, at least in cultured cells, these keratins represent primary translational products encoded by separate mRNA's (19, 21). Second, monoclonal antibody reactivity data preclude certain precursor-product relationships. For example, the 65–67-, 58- or 56-kd keratins are unlikely to give rise to the 48-kd keratin,

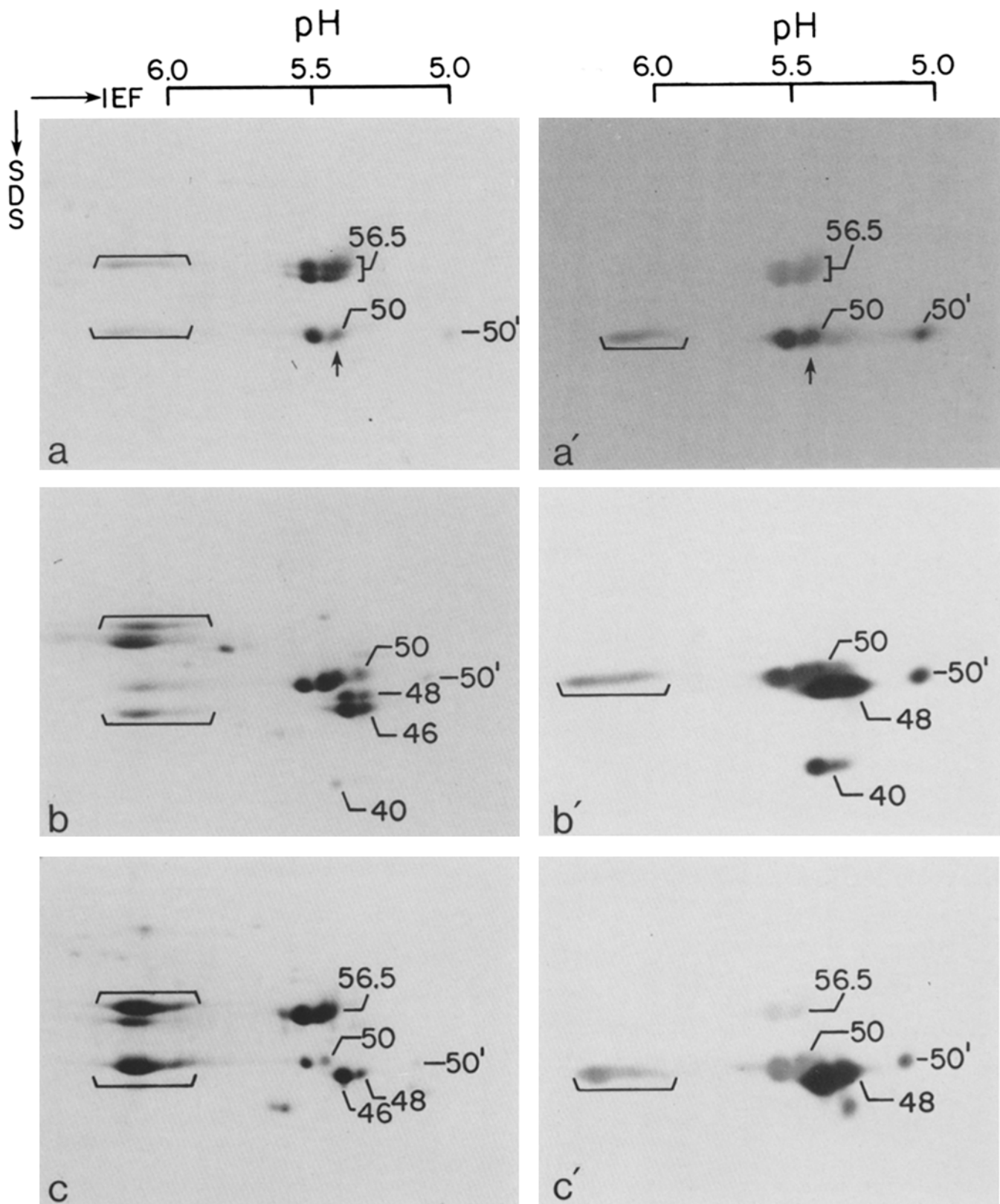


FIGURE 2 Analysis of the acidic human epidermal keratins by two-dimensional gel electrophoresis (equilibrium; IEF-SDS). *a* and *a'*, normal abdominal epidermis; *b* and *b'*, cultured human epidermal cells; *c* and *c'*, psoriasis. *a*–*c* were stained by Coomassie Blue, whereas *a'*–*c'* were stained with AE1 monoclonal antikeratin antibody by the peroxidase-antiperoxidase technique. Keratins are identified by their molecular weights (see text for the nomenclature of Moll et al. [39]). Arrows in *a* and *a'* denote the absence of 48-kD keratin in normal epidermis. The brackets indicate the keratin complexes not resolved during isoelectric focusing but dissociated during SDS gel electrophoresis (40, 74). Note that the psoriatic sample contains both “in vivo” and “culture type” keratins (also see Fig. 3). The 40-kD keratin, however, appears to be characteristic of cultured cells. In Fig. 2*c'*, the minor AE1-reactive spot below the 48-kD keratin was seen only in a few preparations and may represent a degradative product of the 48-kD keratin. A comparison of Figs. 2*c* and *c'* showed that AE1 reacted with the 48, 50, and 56.5-kD keratins with a decreasing order of intensity. Experiments in which the same blot was visualized first with Fast green staining followed by AE1 reaction showed that this variation in staining intensity was not due to a decreased transfer of larger proteins to the paper (see, e.g., Fig. 1, *a* and *b*). Rather, this could be due to either a difference in the number of antigenic determinants per molecule or, perhaps more likely, small differences in antigenic sites (12).

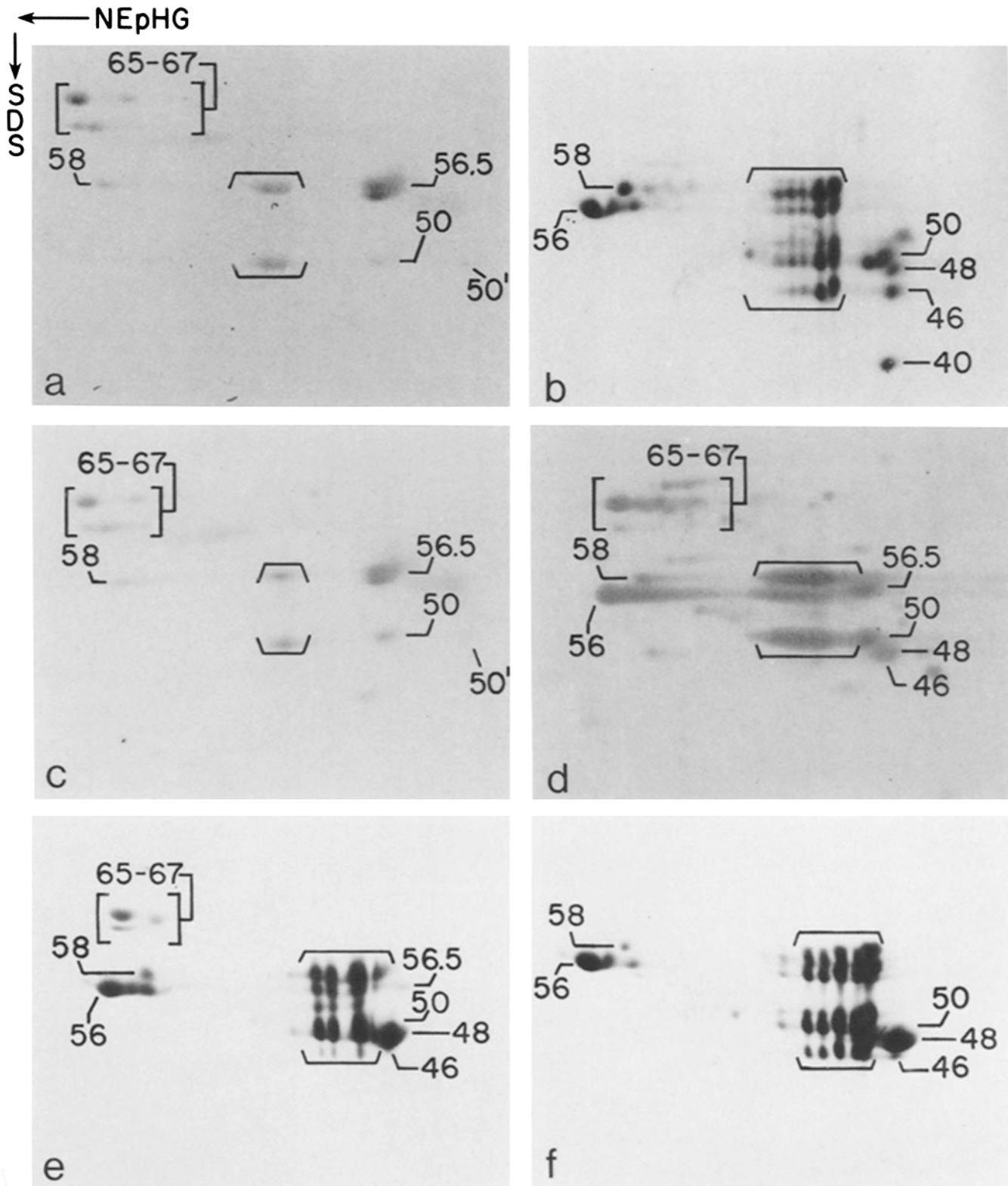
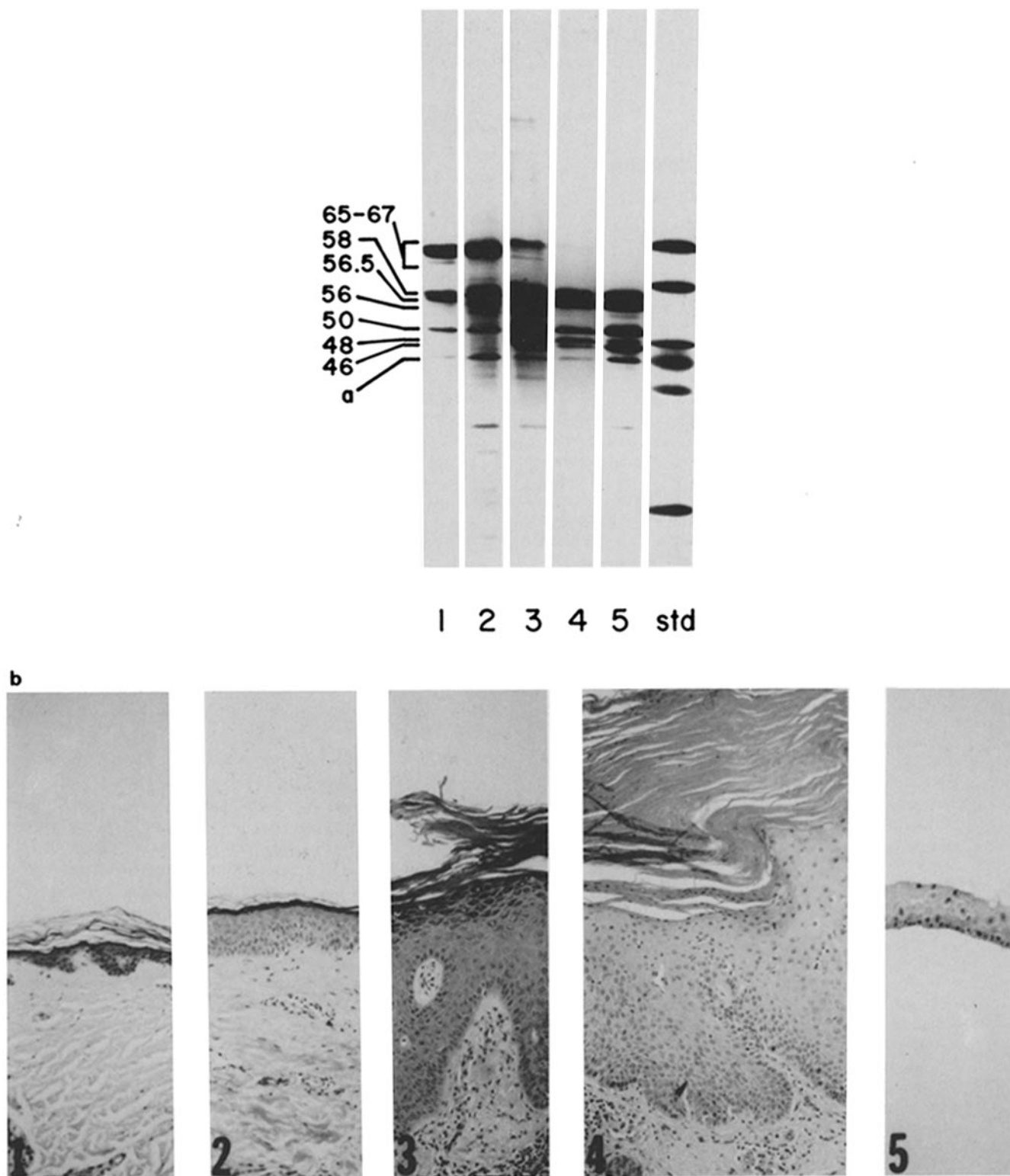


FIGURE 3 Analysis of total human epidermal keratins by two-dimensional gel electrophoresis (nonequilibrium; NEpHG-SDS). The basic proteins are to the left. *a*, normal abdominal epidermis; *b*, cultured newborn foreskin epidermal cells; *c*, ichthyosis vulgaris; *d*, psoriasis; *e*, wart; *f*, basal cell carcinoma. Keratins are visualized after Coomassie Blue staining and are identified by molecular weights. As in Fig. 2, horizontal brackets denote keratins that remain associated as a complex during the first dimensional separation.

since the former are AE1-negative whereas the latter is AE1-positive. Finally, the same amounts of these keratins were detected both in the presence and absence of various protease inhibitors including PMSF, pepstatin, antipain, EDTA, and

EGTA. Boiling the epidermal specimens directly in high concentrations of SDS plus reducing agent, one of the most stringent conditions known to inhibit proteolytic activities, also did not affect the level of these keratins.



**FIGURE 4** A spectrum of keratin expression in psoriasis. (a) SDS gel electrophoresis: water-insoluble cytoskeletal proteins were electrophoresed and stained by Coomassie Blue. Lane 1, normal abdominal epidermis; lane 2, uninvolved skin adjacent to a plaque lesion; lane 3, a psoriatic lesion with a "keratinized" morphology (formation of granular and cornified layers). As reported earlier, nearly one-third of clinically typical lesions of psoriasis showed keratinization to be more prevalent than parakeratinization (see page 142 of [32]; also see below); lane 4, another case of psoriasis showing parakeratinization (formation of a nucleated stratum corneum, which is frequently associated with a lack of underlying granular layer). Lane 5, cultured newborn foreskin keratinocytes. Std, molecular weight standards that are, from top to bottom, bovine serum albumin (68 kd), catalase (60 kd), fumarase (49 kd), ovalbumin (45 kd), aldolase (40 kd), and trypsinogen (24 kd). a denotes residual actin. (b) Histology of the corresponding specimens. Parts of the specimens analyzed (top) were fixed with formalin and processed for routine histology (hematoxylin and eosin staining). Note the parakeratinized morphology of psoriatic specimen no. 4, and the nonkeratinized morphology (a total lack of stratum corneum) of the cross-section of a cultured epidermal colony (specimen no. 5).



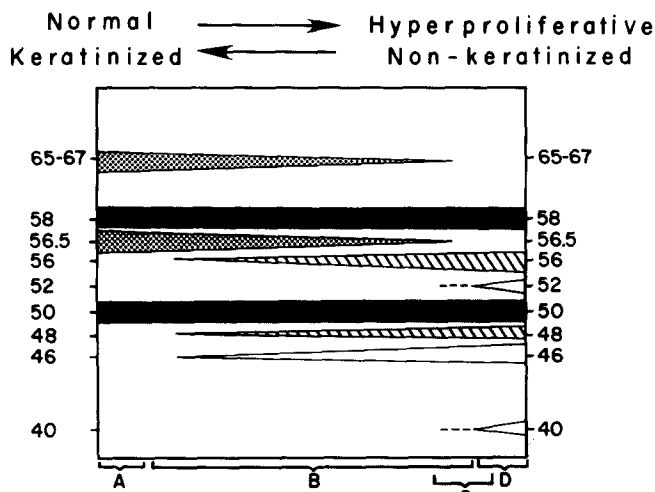


FIGURE 5 A schematic representation of the spectrum of keratin expression in epidermal diseases. The keratin pattern of normal *in vivo* epidermis is shown to the left, that of cultured keratinocytes to the right, and those of various diseases studied so far in between. The black bars denote the acidic 50 kD (AE1; subfamily A) and basic 58 kD (AE3; subfamily B) keratins which are always expressed (constant members, [12]). The stippled bars denote the acidic 56.5-kD (AE1; subfamily A) and basic 65–67-kD (AE3; subfamily B) keratins which represent markers for phenotypic keratinization (68, 72). The hatched bars denote the acidic 48-kD (AE1; subfamily A) and basic 56-kD (AE3; subfamily B) keratins which represent markers for hyperproliferative keratinocytes. All the above-mentioned keratins are keratinocyte-specific. The 40, 46, and 52-kD keratins are present in cultured keratinocytes and some epidermal diseases; these keratins are also found, however, in simple epithelia and therefore are not keratinocyte-specific (open bars). (A) Keratins expressed by normal trunk epidermis and ichthyosis vulgaris (Fig. 1). (B) Keratins expressed in various hyperproliferative epidermal disorders. While the 50- and 58-kD keratins are present throughout the spectrum, the expression of the 65–67 and 56.5-kD keratins (markers for keratinization) and 56, 52, 48, 46, and 40-kD keratins (“culture-type”) was variable and appeared to be related to the degrees of keratinization vs. hyperproliferation. Many disease specimens possessed both “keratinization markers” and “culture-type keratins,” most likely reflecting the heterogeneous expression of these two types of keratins by individual keratinocytes. This explains the apparent complexities in keratin pattern frequently seen in disorders (Figs. 1–3; cf. [41]). The entire spectrum of keratin expression as shown in this diagram can sometimes be seen even within a single disease, such as psoriasis (Fig. 4 and text). (C) The keratin pattern of basal cell carcinoma was very similar to that of cultured epidermal cells (28), except for the absence of 40-kD keratin which was detectable only in cultured cells (Figs. 1–3). (D) Keratinocytes cultured under *in vitro* conditions in the presence of 3T3 feeder cells (47) and various growth-stimulating factors, e.g., epidermal growth factor, vitamin A, hydrocortisone, etc. (Figs. 1–4). By removing these growth factors, the cells can be induced to keratinize partially (12, 22). Values represent keratin molecular weight  $\times 10^{-3}$ .

Thus we have established in many epidermal diseases the existence of a 48-kD keratin (AE1-reactive; subfamily A, [12]; pI 5.1; no. 16 of Moll et al. [39]) and a 56-kD keratin (AE3; subfamily B; pI 7.8; no. 6). Independently, Osber and McGuire (46) have also identified these two keratins in psoriatic epidermis. These two keratins are clearly not disease-specific, however, since they are expressed not only in epidermal disorders with diverse etiology and pathogenesis (Figs. 1–3), but also in normal heel epidermis (8, 21, 39, 40, 72), trunk epidermis induced to hyperproliferate by tape-stripping (R.

A. Weiss and T.-T. Sun, unpublished results), and short-term organ-cultured human epidermis (13, 46). An acidic, water-insoluble protein (band 8) similar to our 48-kD keratin has also been found in mouse epidermis during phorbol ester-induced hyperplasia (48), although the significance of this earlier finding was not discussed. Since epidermal cells in all these diseases or conditions are known or thought to be hyperproliferative (6, 9, 24, 32, 69), such results suggest that the expression of the 48- and 56-kD keratins is related to epidermal hyperproliferation, whether physiological (e.g., normal heel epidermis) or pathological (diseases and tape-stripped epidermis).

Existing data also indicate that these two keratins are expressed in cultured human corneal, conjunctival, esophageal, as well as skin epithelial cells (Figs. 1–4; 10, 21, 43, 61, 74). In sparse cultures, these cells undergo exponential growth with a doubling time of  $\sim 24$  h and thus are clearly hyperproliferative (60). Although the precise turnover rate of these cells in confluent cultures has not yet been established, recent data on cell kinetics (11) and cell shedding (23, 30, 38) suggest that these cells are probably also hyperproliferative. Moreover, recent data by Moll et al. (39, 41) and Nelson et al. (42) showed that the 48- and 56-kD keratins are present in some nonepidermal stratified epithelia normally exhibiting a high turnover rate, as well as in almost all squamous cell carcinomas regardless of their tissue-origin. These findings indicate that the 48- and 56-kD keratins are not epidermis-specific and thus may be regarded as molecular markers for a hyperproliferative state (or an associated, altered differentiated state) of keratinocytes in general.

#### Expression of Other Keratins in Epidermal Diseases

We have previously shown that the 56.5-kD (AE1-reactive; subfamily A, [12]; pI 5.3; no. 10 of Moll et al. [39]) and the 65–67-kD keratins (AE3, subfamily B; pI 6–8; no. 1 and 2) represent molecular markers for phenotypic keratinization (12, 58, 59, 68, 72). Our present finding that in various epidermal diseases the expression of these two keratins correlated well with the degree of morphological keratinization (Fig. 4) provided further support for this concept.

Existing data indicate that the 50/50'-kD (AE1; subfamily A; pI 5–5.3; no. 14/15) and 58-kD (AE3; subfamily B; pI 7.4; no. 5) keratins represent markers for stratified squamous epithelia (43, 68; cf. 39). Results from the present work (Fig. 1) further established that these two keratins are always expressed (constant members; [12]) by epidermal cells under a wide variety of conditions (normal tissue, cell culture, and benign and malignant diseases).

A minor cytoskeletal protein of 52 kD (AE3; subfamily B; pI 6.1; no. 8) was detected in cultured human keratinocytes and occasionally in diseases. Under normal conditions this protein is primarily expressed by simple epithelia (39, 68).

A 46-kD keratin (subfamily A; pI 5.1; no. 17) was detected in various quantities in diseases including BCC (28, 40). In view of the structural similarities among the 46-, 48-, and 50-kD keratins (40), it is somewhat surprising that AE1 antibody selectively recognizes the two latter keratins, but not the 46-kD component (12). Interestingly, the AE1-positive 48- and 50-kD keratins appear to be specific for stratified squamous epithelial cells (39, 43, 68), whereas the AE1-negative 46-kD keratin is expressed not only by keratinocytes, but also by some simple epithelial cells (e.g., HeLa cells; [13, 39–43]).



Although the 40-kd keratin (AE1; subfamily A; pI 5.2; no. 19) can be readily detected in cultured keratinocytes by AE1-antibody staining, it was apparently not expressed to any significant extent in any of the epidermal diseases including neoplasms (Fig. 1; also see below). This suggests that the 40-kd keratin may not be useful as a marker for distinguishing normal vs. neoplastic epidermal tissues.

### *Reciprocal Expression of Molecular Markers for Keratinization and Hyperproliferation*

Terminal differentiation and cell replication are by definition two mutually exclusive cellular events, which maintain a delicate balance. Consistent with this notion, the relative expression of keratinization markers (the 56.5- and 65-67-kd keratins) and hyperproliferation markers (the 48- and 56-kd keratins) by keratinocytes varied in a roughly reciprocal fashion depending on the growth and/or differentiated states of the cells (Figs. 1 and 5). These results provide direct biochemical evidence for the mutual exclusiveness of keratinization (an "advanced" form of epidermal terminal differentiation; [57]) vs. hyperproliferation.

### *Keratins of Basal Cell Carcinoma*

We have confirmed and extended the original observation by Kubilus et al. (28) that the keratin pattern of BCC is very similar to that of cultured epidermal keratinocytes. Our results are also in accordance with Moll et al., who demonstrated that a 46-kd keratin (no. 17) is present in BCC but not in normal epidermis (40; also see 28). However, since this keratin is found not only in cells of the pilosebaceous unit, but also in HeLa cells, cultured normal skin, corneal, conjunctival, and esophageal keratinocytes, as well as in several epidermal diseases including psoriasis (Fig. 4, lane 4; [10, 21, 39, 40, 61, 62, 74]), this keratin is not cell-type-specific and its presence in BCC should not be taken as evidence for a pilosebaceous origin of the neoplasm.

### *48-kd Keratin Expression vs. Suprabasal AE1-Staining Pattern of Epidermal Diseases*

We have recently used AE1 antibody to stain immunohistochemically frozen sections of various epidermal diseases. Although in normal epidermis this antibody selectively stains basal cells (72), it produced a suprabasal staining pattern in all benign epidermal diseases that are 48-kd-keratin positive (70). Although these two events (AE1 suprabasal staining pattern and 48-kd-keratin expression) appear to be closely related, additional experiments will be needed to show whether in hyperproliferative epidermis the 48-kd keratin may be expressed preferentially by suprabasal cells.

### *Concluding Remarks*

When keratinocytes from psoriatic epidermis and basal cell carcinoma are grown in culture, they behave similar to cultured normal epidermal cells (2, 8, 28, 35; M. Jarvinen, S. Passman, I. M. Freedberg, and T.-T. Sun, unpublished results). The reason for this becomes obvious if one assumes that, in culture, the growth of keratinocytes may be stimulated almost fully (position D in Fig. 5), thus obliterating the in vivo differences between normal and diseased tissues.

During recent years, cultured keratinocytes have been used extensively for studying various aspects of "normal" epider-

mal growth and differentiation. However, our results clearly established that as far as keratin expression is concerned, these cells resemble hyperproliferative epidermal conditions and thus may be useful, instead, as a model for studying epidermal hyperplasia. Conversely, our findings also suggest that extrapolation of certain data obtained by using cultured keratinocytes to the normal in vivo situation should be done only with great caution.

Although it is generally agreed that epidermal keratin expression can be influenced by diseases, the question of whether any such changes might be disease-specific and thus of diagnostic value has not yet been settled. Consistent with earlier results by Baden et al. (5), Steinert et al. (54), Hunter and Skerrow (26), and Bowden et al. (8), we have not been able to find any well-defined "disease-specific" keratins in the common hyperproliferative disorders studied. Moreover, our results suggest that there were extensive overlaps among keratins of various diseases (Fig. 1), and that a broad, continuous spectrum of keratin expression can occur even within a given disease (e.g., psoriasis; Fig. 4). These findings provide an explanation for the controversy regarding the presence of the high molecular weight keratins in psoriatic epidermis (1, 5, 8, 37, 50, 54, 66). Our results have also shown that, contrary to some earlier suggestions (1, 71), keratin analysis may not be helpful for the differential diagnosis of most epidermal diseases, or for discriminating benign vs. malignant epithelial lesions (however, for distinguishing carcinomas of simple vs. stratified epithelial origins by keratin analysis, see 39, 41, 42). Finally, the apparent lack of any major, disease-specific keratin changes in the epidermal diseases studied so far implies that keratin abnormalities probably represent the consequence, rather than the cause, of these diseases.

We thank Mikko Jarvinen, Steven Passman, and Irwin M. Freedberg for their early contributions in studying various diseased epidermal keratinocytes in culture, Paula Bonitz and Helen Santana for excellent technical assistance, and Marion Lynch for critical reading of the manuscript.

This investigation was aided in part by grants by the National Institutes of Health (AM 25140, EY 02472 and EY 04722), Estee Lauder Company and Gillette Company. R. Eichner and T.-T. Sun were the recipients of a Dermatology Foundation Fellowship from Avon Products Co. and National Institutes of Health Research Career Development Award (EY0125), respectively.

*Received for publication 24 June 1983, and in revised form 11 October 1983.*

### REFERENCES

1. Adrian, R. M., and H. P. Baden. 1980. Analysis of epidermal fibrous proteins in inflammatory linear verrucous epidermal nevus. *Arch. Dermatol.* 116:1179-1180.
2. Baden, H. P., J. Kubilus, and M. J. MacDonald. 1981. Normal and psoriatic keratinocytes and fibroblasts compared in culture. *J. Invest. Dermatol.* 76:53-55.
3. Baden, H. P., J. Kubilus, K. Rosenbaum, and A. Fletcher. 1982. Keratinization in the Harlequin fetus. *Arch. Dermatol.* 118:14-18.
4. Baden, H. P., and L. D. Lee. 1978. Fibrous proteins of human epidermis. *J. Invest. Dermatol.* 71:148-151.
5. Baden, H. P., N. McGilvray, C. K. Cheng, L. D. Lee, and J. Kubilus. 1978. The keratin polypeptides of psoriatic epidermis. *J. Invest. Dermatol.* 70:294-297.
6. Bennington, J. L. 1969. Cellular kinetics of invasive squamous carcinoma of the human cervix. *Cancer Res.* 29:1082-1088.
7. Bowden, P. E., and W. J. Cunliffe. 1981. Modification of human prekeratin during epidermal differentiation. *Biochem. J.* 199:145-154.
8. Bowden, P. E., E. J. Wood, and W. J. Cunliffe. 1983. Comparison of prekeratin and keratin polypeptides in normal and psoriatic human epidermis. *Biochim. Biophys. Acta.* 743:172-179.
9. Christophers, E., and O. Braun-Falco. 1970. Psoriatic hyperplasia: some measurements. *Br. J. Dermatol.* 83:63-68.
10. Doran, T. I., A. Vidrich, and T.-T. Sun. 1980. Intrinsic and extrinsic regulation of the differentiation of skin, corneal and esophageal epithelial cells. *Cell.* 22:17-25.
11. Dover, R., and C. S. Potten. 1983. Cell cycle kinetics of cultured human epidermal

- keratinocytes. *J. Invest. Dermatol.* 80:423-429.
12. Eichner, R., P. Bonitz, and T.-T. Sun. 1984. Classification of epidermal keratins according to their immunoreactivity, isoelectric point, and mode of expression. *J. Cell Biol.* 98:1388-1396.
  13. Fey, S. J., P. M. Larsen, R. Bravo, A. Celis, and J. E. Celis. 1983. Differential immunological crossreactivity of HeLa keratin antibodies with human epidermal keratins. *Proc. Natl. Acad. Sci. USA.* 80:1905-1909.
  14. Fraki, J. E., K. Thompson, R. A. Briggman, and G. S. Lazarus. 1981. Uninvolved skin from psoriatic patients develops signs of involved psoriatic skin after being grafted onto nude mice. *Science (Wash. DC).* 215:685-687.
  15. Franke, W. W., O. Appelhans, E. Schmid, C. Freudenstein, M. Osborn, and K. Weber. 1979. Identification and characterization of epithelial cells in mammalian tissues by immunofluorescence microscopy using antibodies to prekeratin. *Differentiation.* 15:7-25.
  16. Franke, W. W., D. L. Schiller, R. Moll, S. Winter, E. Schmid, I. Engelbrecht, H. Denk, R. Krepler, and B. Platzter. 1981. Diversity of cytokeratins: differentiation specific expression of cytokeratin polypeptides in epithelial cells and tissues. *J. Mol. Biol.* 153:933-959.
  17. Franke, W. W., E. Schmid, M. Osborn, and K. Weber. 1978. Different intermediate-sized filaments distinguished by immunofluorescence microscopy. *Proc. Natl. Acad. Sci. USA.* 75:5034-5038.
  18. Franke, W. W., K. Weber, M. Osborn, E. Schmid, and C. Freudenstein. 1978. Antibody to prekeratin: decoration of tonofilament-like arrays in various cells of epithelial character. *Exp. Cell Res.* 116:429-445.
  19. Fuchs, E., S. M. Coppock, H. Green, and D. W. Cleveland. 1981. Two distinct classes of keratin genes and their evolutionary significance. *Cell.* 27:75-84.
  20. Fuchs, E., and H. Green. 1978. The expression of keratin genes in epidermis and cultured epidermal cells. *Cell.* 15:887-897.
  21. Fuchs, E., and H. Green. 1980. Changes in keratin gene expression during terminal differentiation of the keratinocyte. *Cell.* 19:1033-1042.
  22. Fuchs, E., and H. Green. 1981. Regulation of terminal differentiation of cultured human keratinocytes by vitamin A. *Cell.* 25:617-625.
  23. Green, H. 1977. Terminal differentiation of cultured human epidermal cells. *Cell.* 11:405-416.
  24. Heenen, H., G. Achten, and P. Galand. 1973. Autoradiographic analysis of cell kinetics in human normal epidermis and basal cell carcinoma. *Cancer Res.* 33:123-127.
  25. Hunter, L., and D. Skerrow. 1981. The proteins of living psoriatic epidermis. *Biochem. Biophys. Acta.* 714:164-169.
  26. Hunter, L., and D. Skerrow. 1981. The effect of increased tissue turnover on the keratinization of human epidermis. *Biochem. Biophys. Acta.* 674:155-159.
  27. Kohler, G. T., and C. Milstein. 1975. Continuous cultures of fused cells secreting antibody of predefined specificity. *Nature (Lond.).* 256:459-497.
  28. Kubilus, J., H. P. Baden, and N. McGilvray. 1980. Filamentous protein of basal cell epithelioma: characteristics in vivo and in vitro. *J. Natl. Cancer Inst.* 65:869-875.
  29. Kubilus, J., J. MacDonald, and H. P. Baden. 1979. Epidermal proteins of cultured human and bovine keratinocytes. *Biochem. Biophys. Acta.* 578:484-492.
  30. Kubilus, J., R. Rand, and H. P. Baden. 1981. Effects of retinoic acid and other retinoids on the growth and differentiation of 3T3-supported human keratinocytes. *In Vitro.* 17:786-795.
  31. Lavker, R. M., and T.-T. Sun. 1983. Rapid modulation of epidermal differentiation by the external environment. *J. Invest. Dermatol.* 80:228-237.
  32. Lever, W. F., and G. Schaumburg-Lever. 1983. *Histopathology of the Skin* (6th Ed.). J. B. Lippincott Co., Philadelphia.
  33. Levine, M., and A. McLeod. 1979. Fibrous proteins of normal and abnormal human epidermis. *Br. J. Dermatol.* 100:401-408.
  34. Levine, M. J., N. McGilvray, and H. P. Baden. 1980. Effect of therapy on keratin polypeptide profile of psoriatic epidermis. *Arch. Dermatol.* 116:1028-1030.
  35. Liu, S.-C., and C. S. Parsons. 1983. Serial cultivation of epidermal keratinocytes from psoriatic plaques. *J. Invest. Dermatol.* 81:54-61.
  36. Loning, T., M. J. Staguet, J. Thivolet, and G. Seifert. 1980. Keratin polypeptide distribution in normal and diseased human epidermis and oral mucosa. *Virchows Arch. A Pathol. Anat. and Histol.* 388:273-288.
  37. Matoltsy, A. G., M. N. Matoltsy, and P. J. Cliffl. 1983. Characterization of keratin polypeptides and psoriatic horny cells. *J. Invest. Dermatol.* 80:185-188.
  38. Milstone, M., J. McGuire, and J. F. LaVigne. 1982. Retinoic acid causes premature desquamation of cells from confluent cultures of stratified squamous epithelia. *J. Invest. Dermatol.* 79:253-260.
  39. Moll, R., W. W. Franke, D. L. Schiller, B. Geiger, and R. Krepler. 1982. The catalog of human cytokeratins: patterns of expression in normal epithelia, tumors and cultured cells. *Cell.* 31:11-24.
  40. Moll, R., W. W. Franke, B. Volc-Platzter, and R. Krepler. 1982. Different keratin polypeptides in epidermis and other epithelia of human skin: a specific cytokeratin of molecular weight 46,000 in epithelia of the pilosebaceous tract and basal cell epitheliomas. *J. Cell Biol.* 95:285-295.
  41. Moll, R., K. Reinhard, and W. W. Franke. 1983. Complex cytokeratin polypeptide patterns observed in certain human carcinomas. *Differentiation.* 23:256-269.
  42. Nelson, W. G., H. Battifora, H. Santana, and T.-T. Sun. 1984. Specific keratins as molecular markers for neoplasms with a stratified epithelial origin. *Cancer Res.* In press.
  43. Nelson, W. G., and T.-T. Sun. 1983. The 50 kd and 58 kd keratin classes as molecular markers for stratified squamous epithelia: cell culture studies. *J. Cell Biol.* 97:244-251.
  44. O'Farrell, P. H. 1975. High resolution two-dimensional electrophoresis of proteins. *J. Biol. Chem.* 250:4007-4021.
  45. O'Farrell, P. Z., H. M. Goodman, and P. H. O'Farrell. 1977. High resolution two-dimensional electrophoresis of basic as well as acidic proteins. *Cell.* 12:1133-1142.
  46. Osber, M. L., and J. McGuire. 1983. A comparison of abundance and labelling pattern of keratins extracted from involved and uninvolved skin of psoriatic patients. *J. Invest. Dermatol.* 80:360a. (Abstr.)
  47. Rheinwald, J. G., and H. Green. 1975. Serial cultivation of strains of human epidermal keratinocytes: the formation of keratinizing colonies from single cells. *Cell.* 6:331-344.
  48. Schweizer, J., and H. Winter. 1982. Changes in regional keratin polypeptide patterns during phorbol ester-mediated reversible and permanently sustained hyperplasia of mouse epidermis. *Cancer Res.* 42:1517-1529.
  49. Skerrow, D. 1977. The isolation and preliminary characterization of human prekeratin. *Biochem. Biophys. Acta.* 494:447-451.
  50. Skerrow, D., and I. Hunter. 1978. Protein modification during the keratinization of normal and psoriatic human epidermis. *Biochem. Biophys. Acta.* 537:474-484.
  51. Skerrow, D., and C. J. Skerrow. 1983. Tonofilament differentiation in human epidermis: isolation and polypeptide chain composition of keratinocyte subpopulations. *Exp. Cell Res.* 143:27-35.
  52. Staguet, M. J., J. Viac, and J. Thivolet. 1981. Keratin polypeptide modifications induced by human papilloma virus. *Arch. Dermatol. Res.* 271:83-90.
  53. Steinert, P. M., and W. W. Idler. 1979. Postsynthetic modification of mammalian epidermal keratin. *Biochemistry.* 18:5664-5669.
  54. Steinert, P. M., G. L. Peck, and W. W. Idler. 1980. Structural changes of human epidermal keratin in disorders of keratinization. In *Biochemistry of Normal and Abnormal Epidermal Keratinization*. I. A. Bernstein and M. Seiji, editors. University of Tokyo Press, Tokyo. 391-406.
  55. Steinert, P. M., and S. H. Yuspa. 1978. Biochemical evidence for keratinization of mouse epidermal cells in culture. *Science (Wash. DC)* 200:1491-1493.
  56. Sun, T.-T., T. I. Doran, and A. Vidrich. 1980. The use of antikeratin antibodies for the identification of cultured epithelial cells. *Birth Defects Original Article Series.* 16:183-196.
  57. Sun, T.-T., R. Eichner, A. Schermer, D. Cooper, W. G. Nelson, and R. A. Weiss. 1984. Classification, expression, and possible mechanisms of evolution of mammalian epithelial keratins: a unifying model. In *Cancer Cell. Vol. 1, The Transformed Phenotype*. A. Levine, W. Topp, G. Vande Woude, and J. D. Watson, editors. Cold Spring Harbor Laboratory, New York. 169-176.
  58. Sun, T.-T., R. Eichner, W. G. Nelson, S. C. G. Tseng, R. A. Weiss, M. Jarvinen, and J. Woodcock-Mitchell. 1983. Keratin classes: molecular markers for different types of epithelial differentiation. *J. Invest. Dermatol.* 81:109s-115s.
  59. Sun, T.-T., R. Eichner, W. G. Nelson, A. Vidrich, and J. Woodcock-Mitchell. 1983. Keratin expression during normal epidermal differentiation. In *Normal and Abnormal Epidermal Differentiation*. M. Seiji and I. A. Bernstein, editors. University of Tokyo Press, Tokyo. 277-291.
  60. Sun, T.-T., and H. Green. 1976. Differentiation of the epidermal keratinocyte in cell culture: formation of the cornified envelope. *Cell.* 9:511-521.
  61. Sun, T.-T., and H. Green. 1977. Cultured epithelial cells of cornea, conjunctiva and skin: absence of marked intrinsic divergence of their differentiated states. *Nature (Lond.).* 269:489-493.
  62. Sun, T.-T., and H. Green. 1978. The keratin filaments of cultured human epidermal cells: formation of intermolecular disulfide bonds during terminal differentiation. *J. Biol. Chem.* 253:2053-2060.
  63. Sun, T.-T., and H. Green. 1978. Immunofluorescent staining of keratin fibers in cultured cells. *Cell.* 14:468-476.
  64. Sun, T.-T., C. Shih, and H. Green. 1979. Keratin cytoskeletons in epithelial cells of internal organs. *Proc. Natl. Acad. Sci. USA.* 76:2813-2817.
  65. Thaler, M., K. Fukuyama, W. L. Epstein, and K. A. Fisher. 1980. Comparative studies of keratins isolated from psoriasis and atopic dermatitis. *J. Invest. Dermatol.* 75:156-158.
  66. Thaler, M. P., K. Fukuyama, N. Inoué, D. L. Coan, and W. L. Epstein. 1978. Two tris-urea-mercaptoethanol extractable polypeptides found uniquely in scales of patients with psoriasis. *J. Invest. Dermatol.* 70:38-41.
  67. Towbin, H., T. Staehelin, and J. Gordon. 1979. Electrophoretic transfer of proteins from polyacrylamide gels to nitrocellulose sheets. *Proc. Natl. Acad. Sci. USA.* 76:4350-4354.
  68. Tseng, S. C. G., M. J. Jarvinen, W. G. Nelson, J.-W. Huang, J. Woodcock-Mitchell, and T.-T. Sun. 1982. Correlation of specific keratins with different types of epithelial differentiation: monoclonal antibody studies. *Cell.* 30:361-372.
  69. Weinstein, G. 1979. Epidermal cell kinetics. In *Dermatology in General Medicine*. T. B. Fitzpatrick, A. Z. Eisen, K. Wolff, I. M. Freedberg, and K. F. Austen, editors. McGraw-Hill, New York.
  70. Weiss, R. A., G. Y. A. Guillet, I. M. Freedberg, E. R. Farmer, E. A. Small, M. M. Weiss, and T.-T. Sun. 1983. The use of monoclonal antibody to keratin in human epidermal disease: alterations in immunohistochemical staining pattern. *J. Invest. Dermatol.* 81:224-230.
  71. Winter, H., J. Schweizer, and K. Goertler. 1983. Keratin polypeptide composition as a biochemical tool for the discrimination of benign and malignant epithelial lesions in man. *Arch. Dermatol. Res.* 275:27-34.
  72. Woodcock-Mitchell, J., R. Eichner, W. G. Nelson, and T.-T. Sun. 1982. Immunolocalization of keratin polypeptides in human epidermis using monoclonal antibodies. *J. Cell Biol.* 95:580-588.
  73. Wu, Y.-J., and J. G. Rheinwald. 1981. A new small (40 kd) keratin filament protein made by some cultured human squamous cell carcinomas. *Cell.* 25:627-635.
  74. Wu, Y.-J., L. M. Parker, N. E. Binder, M. A. Beckett, J. H. Sinard, C. T. Griffiths, and J. G. Rheinwald. 1982. The mesothelial keratins: a new family of cytoskeletal proteins identified in cultured mesothelial cells and nonkeratinizing epithelia. *Cell.* 31:693-703.